

A cross-linked hyaluronan gel accelerates healing of corneal epithelial abrasion and alkali burn injuries in rabbits

Guanghai Yang,* Ladan Espandar,† Nick Mamalits† and Glenn D. Prestwich*

*Department of Medicinal Chemistry and The Center for Therapeutic Biomaterials, The University of Utah, 419 Wakara Way, Suite 205, Salt Lake City, UT 84108-1257, USA, †John A. Moran Eye Center, 65 Mario Capecchi Drive, Salt Lake City, UT 84132, USA

Address communications to:

G. D. Prestwich

Tel.: +1 801-585-9051

Fax: +1 801-585-9053

e-mail: gprestwich@pharm.utah.edu

Abstract

Objective To evaluate the efficacy of a chemically modified and cross-linked derivative of hyaluronan (CMHA-SX) for treatment of corneal epithelial abrasion and standardized alkali burn injuries.

Animals Twelve female New Zealand white rabbits in two groups were used.

Procedures Bilateral 6-mm diameter corneal epithelial abrasions were made in each of six rabbits in one group and 6-mm standardized alkali burn injuries were made in the second group. A 1% CMHA-SX formulation was applied topically four times per day in right eye of each rabbit for 1 week, and phosphate buffered saline (PBS) was placed in left (control) eye of each rabbit. The wound size was determined by staining with 1% fluorescein and photographed at the slit lamp with a digital camera at 0, 1, 2, 3 days postoperatively in the first group and 0, 1, 2, 3, 7, 12 days in the second group. Rabbit corneas were collected for histological examination on day 7 in the first group and day 12 in the second group.

Results Closure of corneal wound in the abrasion model was complete in the CMHA-SX treated eye by 48 h. The wound closure rate and thickness of the central corneal epithelium in the CMHA-SX treated group was greater than in control eyes for both the abrasion and alkali burn injuries. Moreover, the CMHA-SX treated cornea exhibited better epithelial and stromal organization than the untreated control cornea.

Conclusions Chemically modified and cross-linked derivative of hyaluronan improved corneal wound healing and could be useful for treating noninfectious corneal injuries.

Key Words: corneal epithelium, corneal stroma, extracellular matrix, glycosaminoglycan, hyaluronic acid, wound healing

INTRODUCTION

Hyaluronan (hyaluronic acid, HA) is an unsulfated glycosaminoglycan and abundant molecule of the extracellular matrix that facilitates cell proliferation and migration during embryonic tissue development,¹ wound repair,^{2,3} cell migration,⁴ and tumor invasion.⁵ HA is the major component of the vitreous and is the primary glycosaminoglycan in the interfibrillar space of cross-linked collagen matrix in the cornea. The viscoelastic properties of HA have long been utilized in ophthalmic surgery and for engineering vitreous replacements.^{6–8} During intraocular surgeries, HA can protect the corneal endothelium and maintain the anterior chamber depth.^{9–11} Studies have shown that sodium hyaluronate eye drops can increase pre-corneal tear film stability and corneal wettability, and reduce the tear evaporation

rate.^{12–14} In addition, HA is used clinically to protect corneal epithelial cells in patients with dry eye syndromes, including Sjögren's syndrome.^{15–17}

The effect of HA on intracellular signaling and cell behavior is managed by binding to specific cell-surface receptors, including CD44 and the receptor for hyaluronan-mediated motility (RHAMM).¹⁸ The CD44 receptor has been described on normal human corneal epithelial cells¹⁹ and during re-epithelialization.²⁰ CD44 expression is enhanced in inflammation and allograft rejection.²¹ Studies have also shown that CD44 expression is associated with proliferation of epithelial cells.^{22–24} In particular, human corneal epithelial cells cultured in the presence of HA at 0.6 mg/mL showed increased CD44-mediated migration, but no difference in proliferation, relative to controls.²⁵ Similarly, organ cultures of rabbit cornea showed a dose-dependent stimula-

tory effect of HA of epithelial migration that was unique to HA and not produced by addition of other glycosaminoglycans.^{26,27} These *in vitro* results also translated to *in vivo* models, with HA-containing eye drops showing the ability to promote wound repair in a superficial rabbit keratectomy model,²⁸ corneal injuries in diabetic and nondiabetic rats,²⁹ epithelially denuded rabbit corneas,³⁰ and alkali burns in rabbit corneas.^{31,32}

However, the rapid degradation of HA *in vivo* precludes many direct clinical applications. Four decades of chemical modifications of HA have generated derivatives in which the biophysical and biochemical properties, as well as the rates of enzymatic degradation *in vivo* have been manipulated and tailored for specific clinical needs.³³ Chemical modification of HA offers the opportunity to create new biomaterials for biomedical applications^{34,35} – biocompatible and bioactive materials with physical properties optimized to a specific clinical use. We recently developed a thiol-modified and carboxymethylated derivative of HA,^{36–39} called CMHA-S, that was then cross-linked with either poly (ethyleneglycol) diacrylate or by air oxidation to generate disulfide cross-links, thereby producing biocompatible hydrogels. These biocompatible hydrogels have been shown to be biodegradable yet can be formulated to remain in place for several days to several months *in vivo*, based on the requirement for a given reparative and regenerative medicine application.³⁸ Formulations of CMHA-SX are marketed by SentrX Animal Care, Inc., Salt Lake City, UT, for topical wound care and adhesion prevention. To date, however, the ophthalmic uses of CMHA-SX have not been explored in animal models or for clinical veterinary use. In this study, we will evaluate the potential efficacy of a commercial CMHA-SX formulation, canitrX™, for treating corneal epithelial wounds in two standard rabbit models, the superficial corneal abrasion model and the alkali burn model.

MATERIALS AND METHODS

Preparation of CMHA-SX

Hyaluronic acid (950 kDa, Novozymes Biopolymers, Inc., Bagsvaerd, Denmark) was converted to CMHA-S by SentrX Animal Care by modifications of literature procedures,³⁹ allowed to form disulfide cross-links in air, and then formulated into CMHA-SX gels. The gel formulation known as canitrX™ wound healing gel was employed in this study.

Animals

Twelve female New Zealand white rabbits weighing 2–3 kg were used in this study. Six rabbits were used for a cornea epithelial abrasion model, and the other six rabbits were used for a standardized cornea alkali burn model. The experimental protocol and animal care complied with the ‘Guide for the Care and Use of Laboratory Animals’ (Institute of Laboratory Animal Resources, Commission on Life Sciences, National Research Council, Washington, DC; National Academy Press, 1996), and were approved by the

Institutional Animal Care and Use Committee of the University of Utah.

Epithelial abrasion model

After inducing anesthesia by intramuscular injection of each of the six rabbits of the first group with ketamine (2–6 mg/kg) and xylazine (6 mg/kg), the central corneal epithelium was removed with a 6-mm trephine and a No. 15 scalpel blade. One eye of each rabbit was treated topically with CMHA-SX four times per day for 1 week, and the control eye was treated topically with phosphate buffered saline (PBS) four times per day. The wound sizes were determined by staining the surface of the eye with 1% fluorescein, and photographing the corneas at the slit lamp with a digital camera at 0, 24, 48 and 72 h postoperatively. The rabbits were euthanized on day 7 and corneas were collected for histological examination.

Alkali burn model

For the second group of six rabbits, animals were anesthetized and then standardized cornea alkali wounds were produced bilaterally by placing a round 6.0 mm filter paper, soaked in 1 N NaOH, on the central cornea for 60 s.³² Each injured cornea was then rinsed with balanced salt solution (BSS) for 2 min. To the treated eye of each rabbit, CMHA-SX was applied topically four times per day for 1 week. To the control eye of each rabbit, PBS was applied topically four times per day for 1 week. Ciprofloxacin (0.3%) was also applied topically in both eyes during the first application of the CMHA-SX gel or the PBS control. The wound size was determined by staining the surface of the eye with 1% fluorescein and photographing the cornea at the slit lamp with a digital camera on 0, 1, 2, 3, 7 and 12 days postoperatively. Animals were euthanized at 12 days and corneas were collected for histological examination.

Epithelial wound healing

Images were taken at the slit lamp with a digital camera, and the dimensions of the wound area were measured using image analysis software (ImageJ, Scion Corp., Frederick, MD, USA). Wound closure was expressed as a percentage of the initial wound area. The percentage wound size was calculated using the following formula: $D_x/D_0 \times 100$ (%), where D_0 is the dimension of the epithelial abrasion or alkali burn wound area (6.0 mm × 6.0 mm) on day 0, and the D_x is the dimension of the wound area on the day 1, 2, 3, 7 and 12.

Histologic studies

Each cornea was fixed with 10% formaldehyde and dehydrated in a graded series of alcohol and then embedded in paraffin. Six-micrometer sections were cut and stained with hematoxylin and eosin for light microscopic examination. Corneal epithelium thickness was measured using image analysis software (ImageJ, Scion Corp.) at five equidistant sites. Six slides for each of the six treated and six control eyes

were evaluated in each group, and the mean thickness of the corneal epithelium was determined.

Statistical analysis

All data are presented as mean \pm SD. Student's *t*-test (unpaired) was used as indicated in the text to compare continuous variables. The statistical significance level was set at $P < 0.05$.

RESULTS

Corneal epithelial wound healing

We examined the rabbit corneal epithelial wound healing using a slit lamp camera. Immediately after cornea epithelial abrasion, a round 6.0 mm \times 6.0 mm wound was formed. Figure 1 shows the time course of wound closure in the abrasion model, as seen in the fluorescein stained images of the injured corneas at 0, 24, 48, and 72 h postinjury. The difference in healing was most pronounced at 24 h. Quantification of the digital images at the slit lamp camera indicated that wound closure in CMHA-SX treated eyes was $82.8 \pm 8.0\%$ complete, while wound closure in the control eyes was $48.6 \pm 17.2\%$ complete ($P < 0.01$, Fig. 1b). Closure of the corneal wound was complete by 48 h in CMHA-SX treated eyes and by 72 h in the control eyes (Fig. 1a).

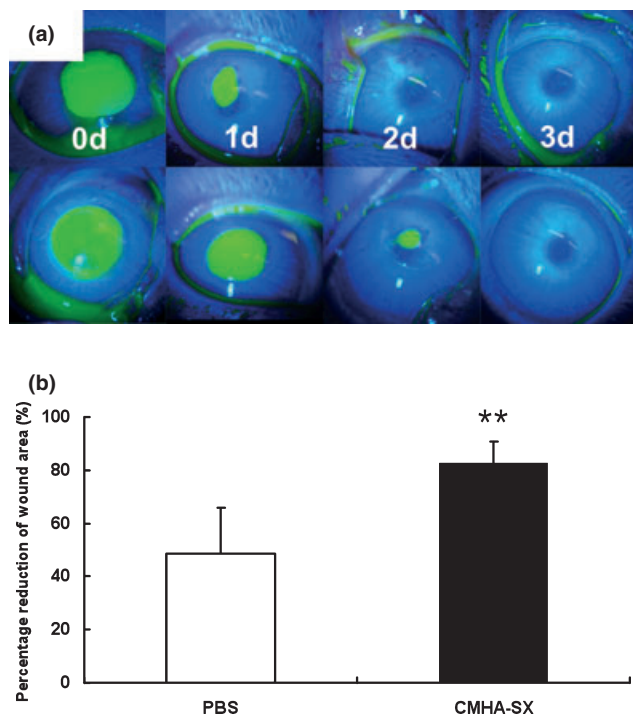


Figure 1. Corneal epithelial wound healing in cornea abrasion model. (Panel a) Fluorescein staining of corneal epithelial abrasions at the indicated times after epithelial abrasion in rabbits (upper panels: CMHA-SX treated group; lower panels: PBS treated control group). (Panel b) Quantitative analysis of corneal epithelial wound healing at 24 h. Data are means \pm SD of value from six treated and six untreated eyes. $**P < 0.01$.

Figure 2 shows the time course of wound closure in the alkali burn model, as seen in the fluorescein stained images of the injured corneas at 0, 1, 2, 3, 7, and 12 days postinjury. Immediately after central corneal alkali burn injuries produced by standardized filter paper disk application, there was no significant difference in the area of the wound between the two groups. At day 1, the wound area for the CMHA-SX eyes was already significantly reduced relative to the control eyes (Fig. 2b, $P < 0.05$). At day 3, the wound sizes were highly significantly different, $74.3 \pm 11.4\%$ in the CMHA-SX treated group compared to $27.7 \pm 5.4\%$ in the PBS treated control group ($P < 0.01$, Fig. 2b). At day 7, closure of the corneal wounds in both CMHA-SX treated eyes and control eyes was incomplete, and the difference in healing was not significantly different at this time point. At day 12, the wound closure was almost complete in the CMHA-SX treated eyes, while wound closure was incomplete in the PBS treated control eyes (Fig. 2b, $P < 0.05$).

Histological finding and epidermal thickness

In the corneal abrasion model, histological analysis demonstrated that the thickness of the central corneal epithelium in the PBS-treated controls appeared thinner than the adjacent uninjured corneal tissues. Indeed, the epithelial thickness of the CMHA-SX gel treated group was significantly greater, and thus closer to normal, than the central epithelium in the PBS treated group (Fig. 3, $P < 0.01$).

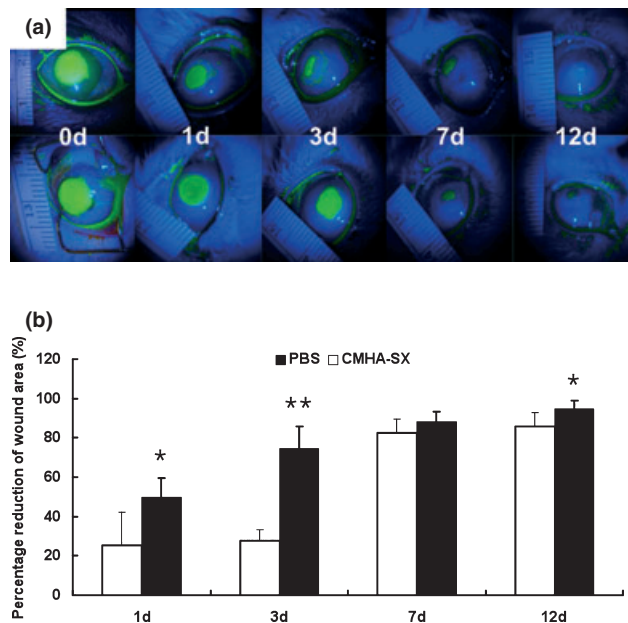


Figure 2. Corneal epithelial alkali burn model: injury and healing. (Panel a) Fluorescein staining of corneal epithelial abrasions at the indicated times after alkali burn injuries in rabbits (upper panels: CMHA-SX treated group, lower panels: PBS instilled control group). (Panel b) Quantitative analysis of corneal epithelial wound healing on day 1, 3, 7 and 12. Data are means \pm SD of value from six treated and six untreated eyes. $*P < 0.05$ and $**P < 0.01$.

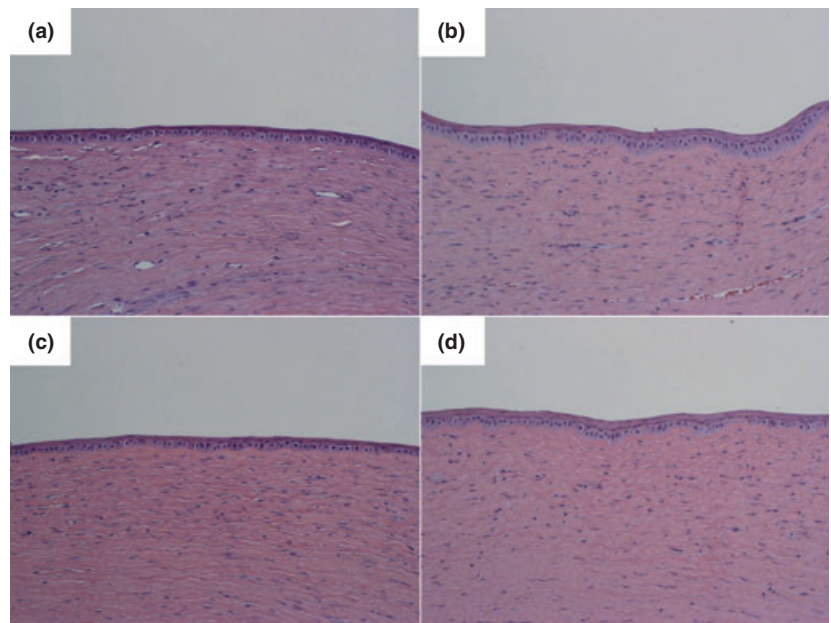


Figure 3. Micrographs showing the central portion of the re-surfaced corneal epithelium at day 7 after creating the superficial epithelial abrasion (a, b) or day 12 after the alkali burn injury (c, d). (Panels a, c) PBS treated eyes; (panels b, d) CMHA-SX treated eyes; H&E staining, $\times 200$). (Panel e) Corneal epidermal thickness for eyes treated with CMHA-SX gel compared with PBS treated control eyes at day 7 after epithelial abrasion injury (** $P < 0.01$). (Panel f) Corneal epidermal thickness for eyes treated with CMHA-SX gel compared with PBS treated control at day 12 after the alkali burn injury (** $P < 0.01$).

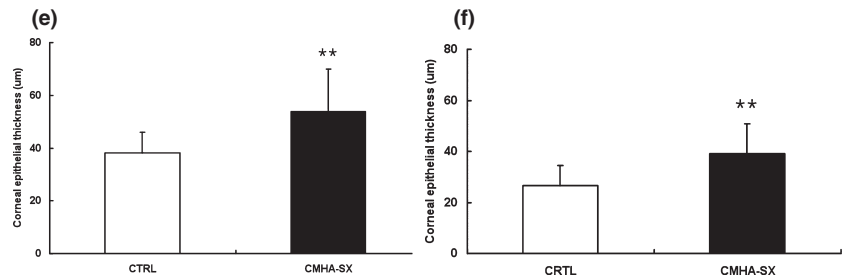
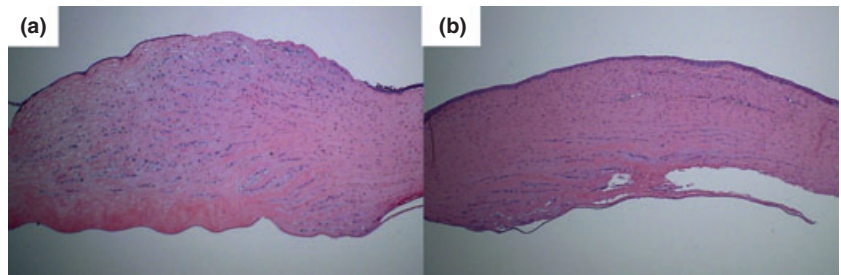


Figure 4. Histology of alkali burn healing. Left: Day 12 after 1 N NaOH burn treated with PBS only, showing central wound with unhealed corneal epithelium. Right, central epithelium and corneal stroma in eyes treated with CMHA-SX, showing a better organization than control (H&E staining, $\times 40$).



In the alkali burn injury, at Day 12 the eyes treated with CMHA-SX gel, exhibited better organization of the central epithelium as well as corneal stroma than the control cornea. In contrast, a central edematous wound with unhealed corneal epithelium in PBS treated control eyes was clearly evident (Fig. 4). The H&E staining also indicated that the re-epithelialization was complete in CMHA-SX treated eyes, but not in control eyes.

DISCUSSION

Hyaluronic acid is widely used in the clinic for viscosurgery, viscosupplementation, treatment of osteoarthritis and dry eye syndromes. However, it is readily degraded in the eye

and in cutaneous wounds. We therefore sought an HA derivative with tunable biomaterial properties that would retain the important biology of HA, while extending its useful half-life *in vivo*. Using a clinically driven strategy^{34,36} HA was modified to contain cross-linkable thiol residues.³⁶⁻³⁹ The resulting derivative, CMHA-S, was allowed to cross-link by disulfide bond formation into CMHA-SX. CMHA-SX films and gels, whether cross-linked by disulfide bonds or with a homobifunctional thiol-reactive cross-linker, accelerated re-epithelialization in acute full-thickness wounds in mice³⁴ and in rats (Yang G, Mann BK, Prestwich GD, personal communication); moreover, the thickness and quality of the regenerated dermis was significantly better than in untreated wounds. In addition, the CMHA-SX films

and gels have been shown to be effective *in vivo* for the treatment of injured vocal folds⁴⁰ for scar-free healing after endoscopic sinus surgery,⁴¹ for reducing stenosis after tracheal injury,⁴² and for reducing or eliminating postsurgical adhesions after cardiac,⁴³ abdominal,⁴⁴ and tendon surgery.⁴⁵

The research described herein constitutes the first evaluation of the efficacy of CMHA-SX on ophthalmic injuries using both the rabbit corneal epithelial abrasion and standardized corneal alkali burn models. These two injury models have been widely used to evaluate the wound healing process in the corneal epithelium.^{46,47} While the corneal epithelial abrasion involves injury to only the surface epithelium, the alkali burn can penetrate the epithelium and damage both stromal and endothelial layers. We investigated the effect of CMHA-SX on a superficial abrasion model, and then we also used the more severe alkali burn model to quantitatively analyze the effect of CMHA-SX on corneal wound healing.

Several literature studies describe the effects of different concentrations of unmodified HA, as sodium hyaluronate, in supporting corneal epithelial repair after injury. For example, 0.2% and 0.4% solutions of 800–1400 kDa HA applied at 2, 4, 6, 24, 28, and 30 h after injury showed equivalent enhancement of epithelial healing of an abrasive injury at 12, 24, and 48 h. Lower concentrations were ineffective, and the concentration dependence was considered to be indicative of a purely pharmacological effect of HA.³⁰ In both diabetic and nondiabetic rats, 0.3% HA (840 kDa) and to a lesser extent 0.1% HA, increased the healing rates of debrided corneas relative to PBS controls.²⁹ Neither 0.03% HA nor 3.0% chondroitin sulfate were effective in promoting healing. Finally, in the alkali burn corneal injury model in rabbits, both 1% and 2% HA solutions applied topically three times per day for 1 and 3 days, and 1, 2, 4, and 8 weeks postinjury.³¹ There was no difference between HA and PBS treatments in the first 2 days, but in the late healing phase, from 16 to 40 days postinjury, the HA group had significantly smaller epithelial defect areas compared to the PBS controls. In a subsequent study, this group found reduced polymorphonuclear leukocytes during early healing, and a smaller defect area after 5 days in the 1% HA group compared to PBS controls.³² However, after 3 weeks, the defects were not significantly different in size.

In this study, a cross-linked and chemically modified HA derivative successfully used to enhance healing in cutaneous injuries³⁴ and reduce scarring following surgical injuries,^{42–45} was evaluated for the first time in an preliminary study of an ophthalmic injury. Indeed, CMHA-SX significantly accelerated corneal epithelial wound healing compared to the PBS controls, even in healthy young rabbits with a rather superficial injury. The acceleration was equivalent to that cited in the literature for treatment of abrasive corneal injuries with unmodified HA. A more detailed study, including a direct comparison of HA and CMHA-SX, would be required to determine if the cross-link stabilized

CMHA-SX exhibited specific clinical or pharmacological advantages. Similarly, the acceleration of wound healing in the alkali burn injury model also supported the hypothesis that a longer-lasting cross-linked HA derivative, such as CMHA-SX, could enhance the repair of a more severe corneal injury. In this case, however, it appears from our preliminary study that CMHA-SX may have had an earlier, longer-lived and more robust effect on corneal repair. We observed significant improvements at 1 and 3 days postinjury with CMHA-SX, vs. 5 days with HA. We observed significant improvement at 12 days with CMHA-SX, vs. no significant effect at 21 days with HA.

In addition to the enhanced rate of healing, CMHA-SX appeared to significantly improve the quality of the healed corneal epithelium. For both the superficial injury and the alkali burn injury, the thickness of the central corneal epithelium in the CMHA-SX gel treated groups was significantly greater than the thickness in the PBS treated control eyes. Moreover, the stroma appeared better organized and thinner in CMHA-SX treated eyes, further suggesting that rapid re-epithelialization may reduce repopulation of the stroma and limit additional stromal trauma.

In conclusion, the present preliminary study shows promising results for the use of topically applied CMHA-SX for the treatment of two different corneal injuries. These striking results provide impetus to examine the use of CMHA-SX for the treatment of corneal injuries in small animal and equine veterinary practice, including potentially larger clinical sample sizes and comparison with unmodified HA. The present data also suggest the need for further mechanistic studies that would include the stromal and endothelial healing in the deep alkali burn wound injury.

ACKNOWLEDGMENTS

We thank the Centers of Excellence Program of the State of Utah for support of the Center for Therapeutic Biomaterials, and the University of Utah for Virtual Incubator Program award on behalf of Sentrax Animal Care, Inc. for support of this research.

CONFLICT OF INTEREST

GDP is a co-founder of and holds equity in Glycosan BioSystems, Carbylan Biosurgery, and Sentrax Animal Care, which use the chemically modified HA technology described herein. GY, LE, and NM disclose no conflicts.

REFERENCES

1. Toole BP. Hyaluronan in morphogenesis. *Journal of Internal Medicine* 1997; **242**: 35–40.
2. Longaker M, Adzick N, Hall J *et al.* Studies in fetal wound healing: VII. Fetal wound healing may be modulated by hyaluronic acid stimulating activity in amniotic fluid. *Journal of Pediatric Surgery* 1990; **25**: 430–433.

3. Chen WYJ, Abatangelo G. Functions of hyaluronan in wound repair. *Wound Repair and Regeneration* 1999; **7**: 79–89.
4. Rilla K, Lammi MJ, Sironen R *et al.* Changed lamellipodial extension, adhesion plaques and migration in epidermal keratinocytes containing constitutively expressed sense and antisense hyaluronan synthase 2 (Has2) genes. *Journal of Cell Science* 2002; **115**: 3633–3643.
5. Toole BP, Wight TN, Tammi MI. Hyaluronan-cell interactions in cancer and vascular disease. *Journal of Biological Chemistry* 2002; **277**: 4593–4596.
6. Polack FM. Penetrating keratoplasty using MK stored corneas and Na Hyaluronate (Healon). *Transactions of the American Ophthalmological Society* 1982; **80**: 248–261.
7. Laflamme MY, Swieca R. A comparative study of two preservative-free tear substitutes in the management of severe dry eye. *Canadian Journal of Ophthalmology* 1988; **23**: 174–176.
8. Sand BB, Marner K, Norn MS. Sodium hyaluronate in the treatment of keratoconjunctivitis sicca. A double masked clinical trial. *Acta Ophthalmologica (Copenhagen)* 1989; **67**: 181–183.
9. Koch D, Liu J, Glasser D *et al.* A comparison of corneal endothelial changes after use of Healon or Viscoat during phacoemulsification. *American Journal of Ophthalmology* 1993; **115**: 188–201.
10. Volker-Dieben H, Regensburg H, Kruit P. A double-blind, randomized study of Healon GV compared with Healon in penetrating keratoplasty. *Cornea* 1994; **13**: 414–417.
11. Inoue M, Tanaka Y, Sugita N *et al.* Improvement of long-term prognosis in patients with ovarian cancers by adjuvant sizofiran immunotherapy: a prospective randomized controlled study. *Biotherapy* 1993; **6**: 13–18.
12. Hamano T, Horimoto K, Lee M *et al.* Sodium hyaluronate eye drops enhance tear film stability. *Japanese Journal of Ophthalmology* 1996; **40**: 62–65.
13. Tsubota K, Yamada M. Tear evaporation from the ocular surface. *Invest Ophthalmological and Visual Sciences* 1992; **33**: 2942–2950.
14. Snibson G, Greaves J, Soper N *et al.* Precorneal residence times of sodium hyaluronate solutions studied by quantitative gamma scintigraphy. *Eye* 1990; **4**: 594–602.
15. Shimmura S, Ono M, Shinozaki K *et al.* Sodium hyaluronate eye drops in the treatment of dry eyes. *British Journal of Ophthalmology* 1995; **79**: 1007–1011.
16. Aragona P, Di Stefano G, Ferreri F *et al.* Sodium hyaluronate eye drops of different osmolarity for the treatment of dry eye in Sjogren's syndrome patients. *British Journal of Ophthalmology* 2002; **86**: 879–884.
17. Troiano P, Monaco G. Effect of hypotonic 0.4% hyaluronic acid drops in dry eye patients: a cross-over study. *Cornea* 2008; **27**: 1126–1130.
18. Turley EA, Noble PW, Bourguignon LY. Signaling properties of hyaluronan receptors. *Journal of Biological Chemistry* 2002; **277**: 4589–4592.
19. Zhu S, Nolle B, Dunker G. Expression of the adhesion molecule CD44 on human corneas. *British Journal of Ophthalmology* 1997; **81**: 80–84.
20. Yu F, Guo J, Zhang Q. Expression and distribution of adhesion molecule CD44 in healing corneal epithelia. *Investigational Ophthalmology and Visual Sciences* 1998; **5**: 710–717.
21. Aruffo A. CD44: one ligand, two functions. *Journal of Clinical Investigation* 1996; **98**: 2191–2192.
22. Mackay CR, Terpe HJ, Stauder R *et al.* Expression and modulation of CD44 variant isoforms in humans. *Journal of Cell Biology* 1994; **124**: 71–82.
23. Lesley J, Hascall VC, Tammi M *et al.* Hyaluronan binding by cell surface CD44. *Journal of Biological Chemistry* 2000; **275**: 26967–26975.
24. Abbasi AM, Chester KA, Talbot IC *et al.* Cd44 is associated with proliferation in normal and neoplastic human colorectal epithelial cells. *European Journal of Cancer* 1993; **29A**: 1995–2002.
25. Gomes JA, Amankwah R, Powell-Richards A *et al.* Sodium hyaluronate (hyaluronic acid) promotes migration of human corneal epithelial cells in vitro. *British Journal of Ophthalmology* 2004; **88**: 821–825.
26. Nishida T, Nakamura M, Mishima H *et al.* Hyaluronan stimulates corneal epithelial migration. *Experimental Eye Research* 1991; **53**: 753–758.
27. Nakamura M, Hikida M, Nakano T. Concentration and molecular weight dependency of rabbit corneal epithelial wound healing on hyaluronan. *Current Eye Research* 1992; **11**: 981–986.
28. Tani E, Katakami C, Negi A. Effects of various eye drops on corneal wound healing after superficial keratectomy in rabbits. *Japanese Journal of Ophthalmology* 2002; **46**: 488–495.
29. Nakamura M, Sato N, Chikama TI *et al.* Hyaluronan facilitates corneal epithelial wound healing in diabetic rats. *Experimental Eye Research* 1997; **64**: 1043–1050.
30. Camillieri G, Bucolo C, Rossi S *et al.* Hyaluronan-induced stimulation of corneal wound healing is a pure pharmacological effect. *Journal of Ocular Pharmacology and Therapeutics* 2004; **20**: 548–553.
31. Chung J, Fagerholm P, Lindstrom B. Hyaluronate in healing of corneal alkali wound in the rabbit. *Experimental Eye Research* 1989; **48**: 569–576.
32. Chung J-H, Park Y-K, Park S-M *et al.* Effect of Na-hyaluronan on stromal and endothelial healing in experimental corneal alkali wounds. *Ophthalmological Research* 1999; **31**: 432–439.
33. Prestwich GD, Kuo J-W. Chemically-modified HA for therapy and regenerative medicine. *Current Pharmaceutical Biotechnology* 2008; **9**: 242–245.
34. Prestwich GD. Engineering a clinically-useful matrix for cell therapy. *Organogenesis* 2008; **4**: 42–47.
35. Allison D, Grande-Allen K. Hyaluronan: a powerful tissue engineering tool. *Tissue Engineering* 2006; **12**: 2131–2140.
36. Prestwich GD. Simplifying the extracellular matrix for 3-D cell culture and tissue engineering: a pragmatic approach. *Journal of Cellular Biochemistry* 2007; **101**: 1370–1383.
37. Shu XZ, Liu Y, Luo Y *et al.* Disulfide cross-linked hyaluronan hydrogels. *Biomacromolecules* 2002; **3**: 1304–1311.
38. Shu XZ, Liu Y, Palumbo FS *et al.* In situ crosslinkable hyaluronan hydrogels for tissue engineering. *Biomaterials* 2004; **25**: 1339–1348.
39. Shu XZ, Ahmad S, Liu Y *et al.* Synthesis and evaluation of injectable, in situ crosslinkable synthetic extracellular matrices for tissue engineering. *Journal of Biomedical Materials Research A* 2006; **79**: 902–912.
40. Duffo S, Thibeault SL, Li W *et al.* Vocal fold tissue repair in vivo using a synthetic extracellular matrix. *Tissue Engineering* 2006; **12**: 2171–2180.
41. Proctor M, Proctor K, Shu XZ *et al.* Composition of hyaluronan affects wound healing in the rabbit maxillary sinus. *American Journal of Rhinology* 2006; **20**: 206–211.
42. Sondrup C, Liu Y, Shu XZ *et al.* Cross-linked hyaluronan-coated stents in the prevention of airway stenosis. *Otolaryngology-Head & Neck Surgery* 2006; **135**: 28–35.
43. Connors RC, Muir JJ, Liu Y *et al.* Postoperative pericardial adhesion prevention using Carbylan-SX in a rabbit model. *Journal of Surgical Research* 2007; **140**: 237–242.

44. Liu Y, Shu XZ, Prestwich GD. Reduced postoperative intra-abdominal adhesions using carbylan-SX, a semisynthetic glycosaminoglycan hydrogel. *Fertility & Sterility* 2007; **87**: 940–948.
45. Liu Y, Skardal A, Shu XZ *et al.* Prevention of peritendinous adhesions following flexor tendon injury with Carbylan™-SX, a semisynthetic glycosaminoglycan hydrogel. *Journal of Orthopedic Research* 2007; **26**: 562–569.
46. Bonfiglio V, Camillieri G, Avitabile T *et al.* Effects of the COOH-terminal tripeptide alpha-MSH(11-13) on corneal epithelial wound healing: role of nitric oxide. *Experimental Eye Research* 2006; **83**: 1366–1372.
47. Pfister RR. The healing of corneal epithelial abrasions in the rabbit: a scanning electron microscope study. *Investigational Ophthalmology* 1975; **14**: 648–661.